

Myriad™

Soft Tissue Bioscaffold

Clinical Case Series

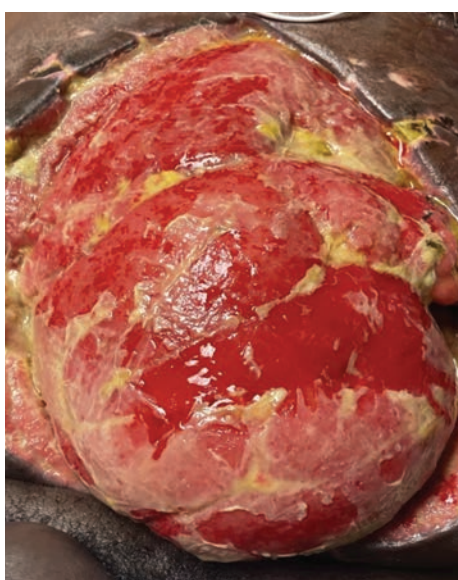Abdominal Defects



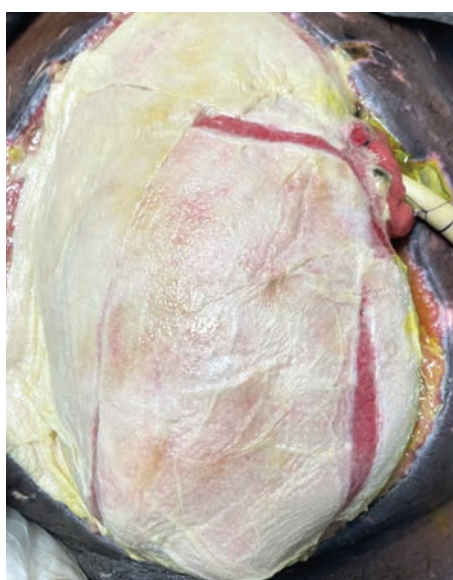
Clinical Case Series: Abdominal Defects

Gunshot wound

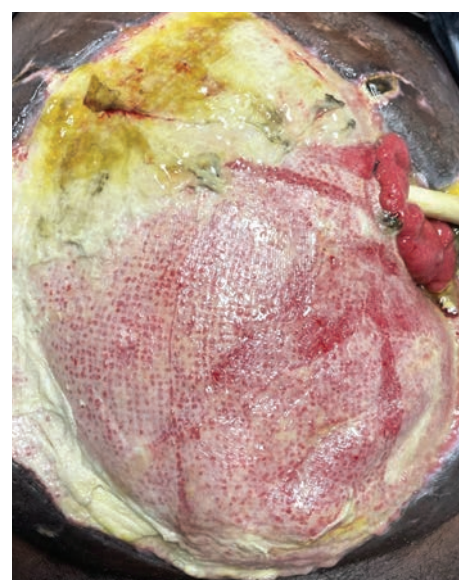
44-Year-old male. Presented with a gunshot wound to the abdomen and chest. Initial procedures included a laparotomy for hemorrhage control and multiorgan injury and resulted in loss of domain. Primary closure of the fascia was not possible; therefore **Myriad** was used to facilitate wound closure. The approximate defect size was:: 25 x 10 cm. **Myriad Morcells™** 2000 mg was applied and hydrated in situ with sterile saline and blood followed by **Myriad Matrix™** devices, 10 x 20 cm (3-layer), placed underneath a contact layer and wet-to-dry dressings. At day 7, budding of granulation tissue was observed. By day 12, significant granulation tissue could be seen. Firmly adhered residual **Myriad** was hydrated and kept intact while non-adherent residual **Myriad** was gently debrided. At day 16, **Myriad** was observed to be integrating. At day 27, significant tissue formation was noted. At day 36, the well-vascularized neodermis had filled to the level of the surrounding healthy tissue with significant reduction in defect volume. A STSG was performed 10 days later. On day 59, 21 days post STSG, there was 90% take of the graft. No complications were reported.



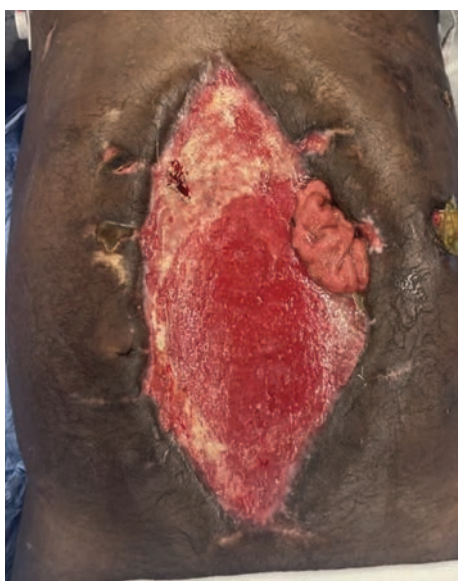Pre-operative Assessment



Day 7



Day 16



Day 36



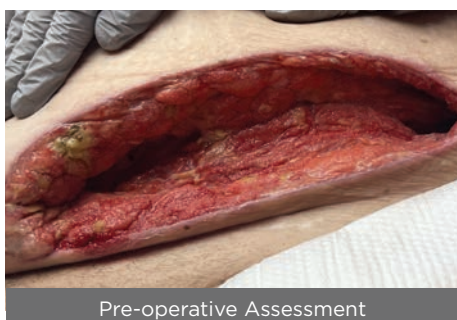Day 59

CC.0191

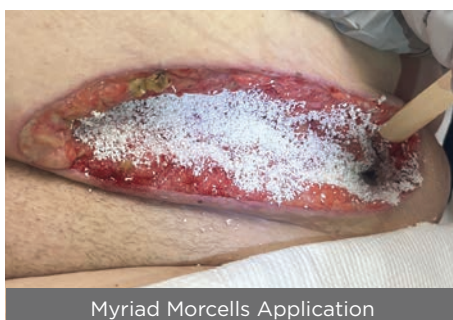Clinical Case Series: Abdominal Defects

Abdominal trauma

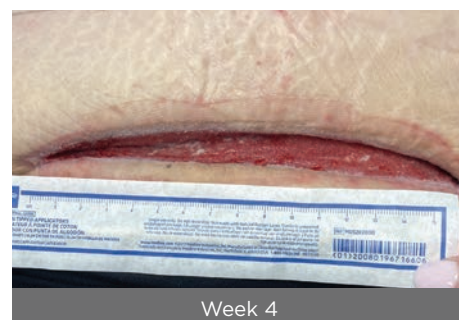61-Year-old, female sustained a full thickness lower left abdomen wound following a MVA. Approximate size: 12 x 36 x 2 cm. Initial procedures included an exploratory laparotomy with right colectomy, small bowel resection and segmental left colon resection. After multiple laparotomies and closure of the abdominal wall, **Myriad** was used to aid in wound closure. **Myriad Morcells** 1000 mg was hydrated in situ with sterile saline and blood followed by NPWT (125 mmHg). By week 4, there was significant reduction in depth and area. The patient was lost to follow up prior to full epithelialization.



Pre-operative Assessment



Myriad Morcells Application

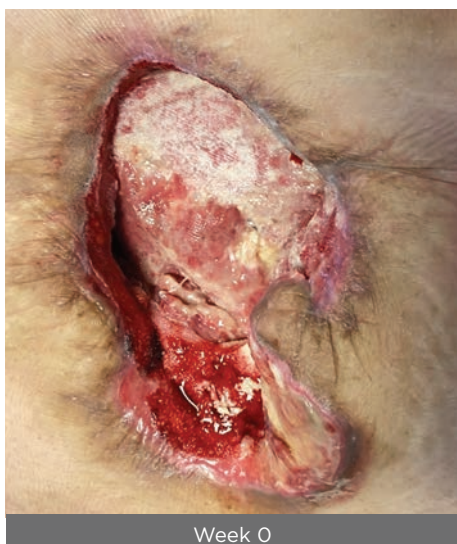

Week 4

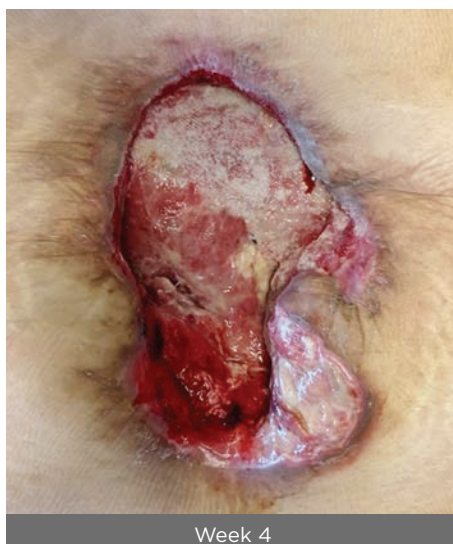CC.0190

Dehiscence following ventral hernia repair

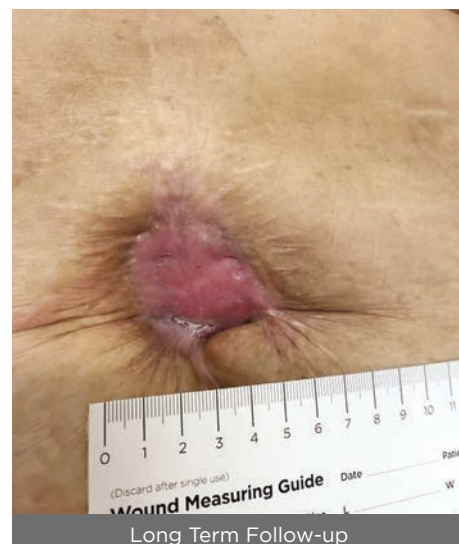64-Year-old, female. Full thickness dehiscence with exposed mesh following ventral hernia repair. Approximate size: 19 x 16 x 3 cm with undermining at 3 o'clock. **Myriad Morcells** 1000 mg, dry, was applied along the deepest part of the wound, then rehydrated in sterile saline, followed by NPWT. At week 4, filling of depth with vascularized tissue was noted. The patient was lost to follow up for 3 months. At 5 months, the wound had healed via secondary intention with no ex plantation of the synthetic mesh.



Week 0



Week 4



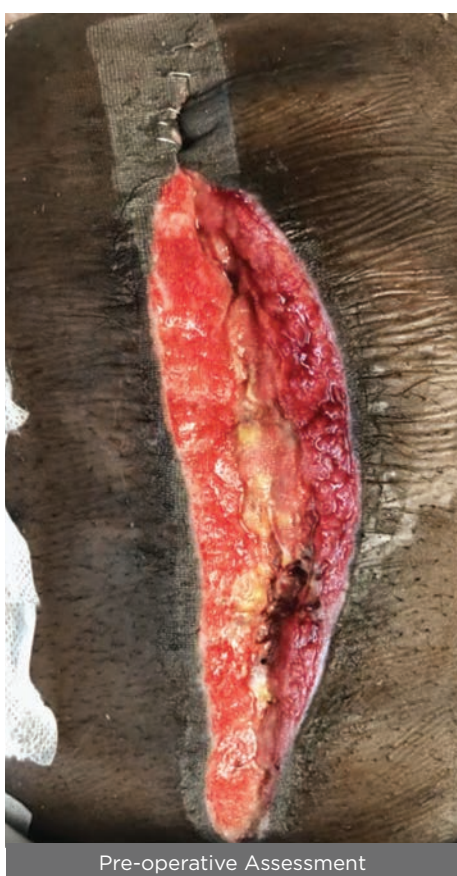Long Term Follow-up

CC.0173

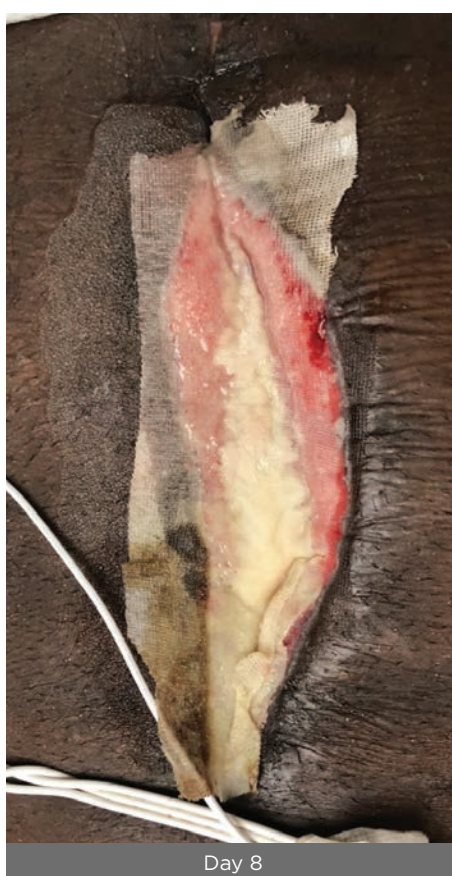Clinical Case Series: Abdominal Defects

Abdominal dehiscence following hernia repair and reinforcement

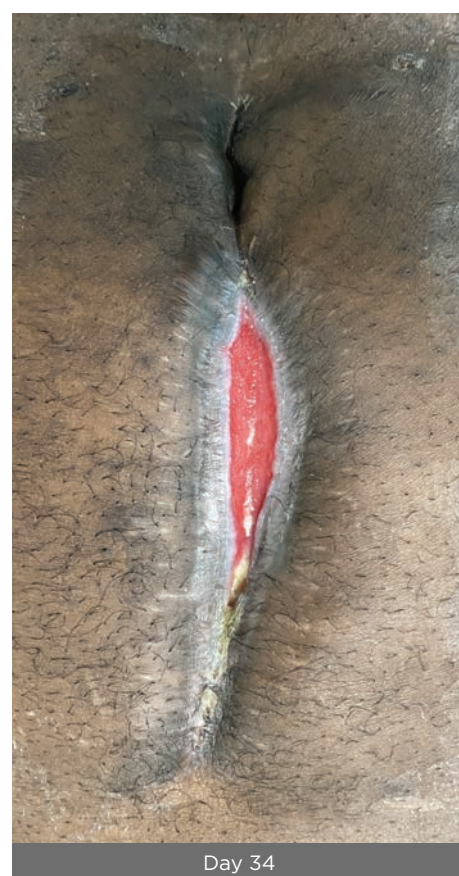47-Year-old male with no significant medical history presented with surgical dehiscence and infection following repair and reinforcement for an incarcerated umbilical hernia with incarcerated fat. With subsequent adjacent skin necrosis, the abdominal defect measured approximately 6.5 x 2 x 6 cm (max depth). After incision and drainage and another debridement, a loss of domain meant primary closure was not an option. **Myriad** was used to help facilitate wound closure with a planned ventral hernia. **Myriad Morcells** 1000 mg was hydrated in situ with sterile saline and blood. A petroleum-based contact layer, gauze and a dry dressing was applied over top. At day 8, **Myriad** was observed to be integrating well with vascularized tissue visible beneath the contact layer. At day 34, there was significant reduction in depth and area with wound epithelialization evident. Patient was lost to follow-up after discharge.



Pre-operative Assessment



Day 8



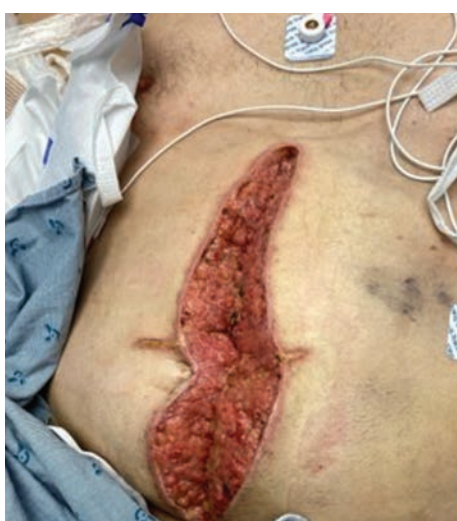Day 34

CC.0192

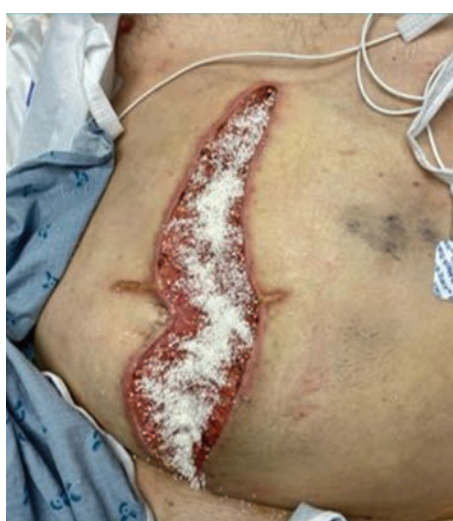Clinical Case Series: Abdominal Defects

Abdominal dehiscence following motor vehicle accident

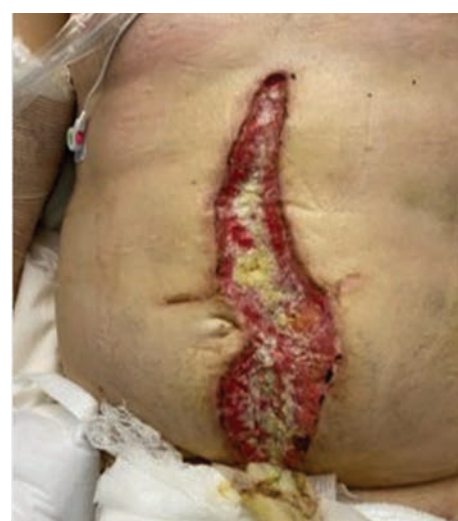49-Year-old male. Presented with surgical dehiscence of the facial layer following a full thickness midline abdominal wound due to a motor vehicle accident. Other complications included hypotension, ruptured liver and bladder and the patient had also undergone a laparotomy, liver and mesenteric repairs. **Myriad Morcells** 1000 mg was hydrated in situ with sterile saline and blood and covered with NPWT. At day 4, **Myriad** was observed to be well adhered and integrating with budding granulation tissue observed. By week 2, **Myriad** was 80% integrated with significant granulation tissue noted. At week 3, there was 90% integration and granulation tissue was filling in the depth of the wound. At week 6, the wound had fully healed with no complications and no recurrence at 1 month post closure.



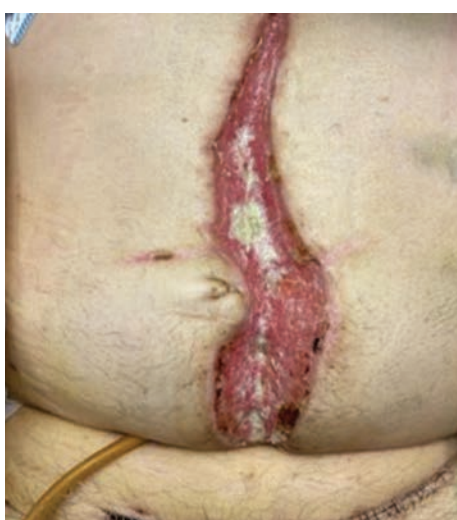Pre-operative Assessment



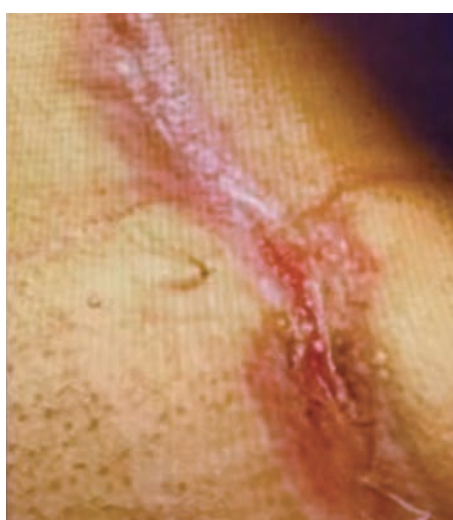Myriad Morcells application



Week 2



Week 3



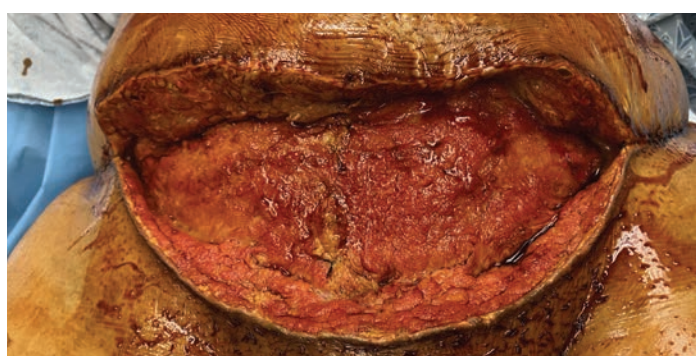Week 6

CC.0072.01

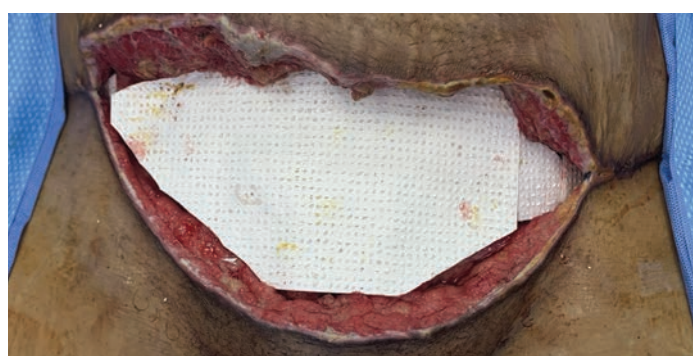Clinical Case Series: Abdominal Defects

Infected Abdominoplasty

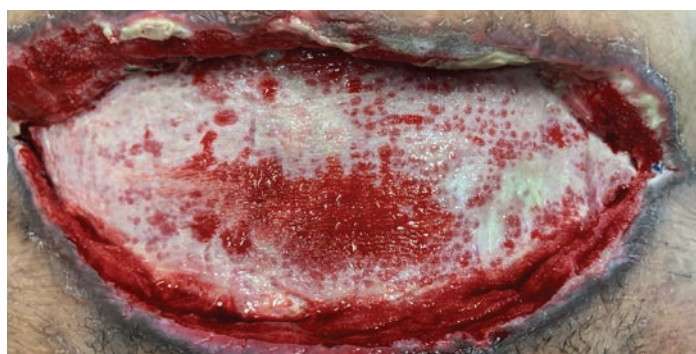41-Year-old female presented to the ER with an abdominal soft tissue infection following an abdominoplasty overseas nine days prior to arrival at the hospital. Betadine-soaked gauze was placed and 2 days later, subsequent debridements were performed followed by NPWT. **Myriad Matrix** (5-layer) was placed covering the entire defect. Xeroform® was sutured to the wound bed and NPWT applied – Xeroform® was left in place for 2 weeks. At 2 weeks, the wound depth had filled in with healthy granulation tissue observed. **Myriad** was approximately 50% integrated. NPWT was continued. At week 5, **Myriad** had fully incorporated resulting in healthy neodermis. Home health was changing NPWT 2x per week. At week 10, there was an approximate 90% reduction in depth and >80% reduction in wound size. NPWT had ceased 1 week prior. The patient went on to close via secondary intention.



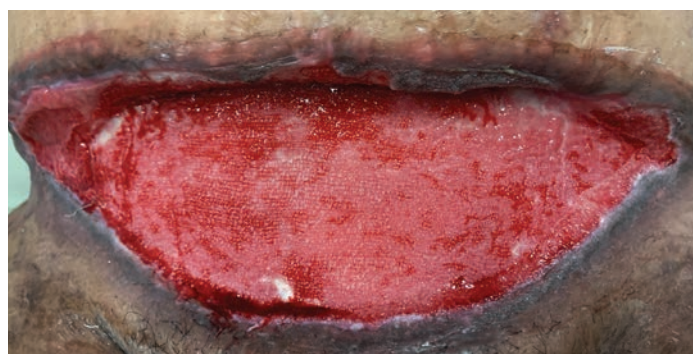Initial Defect



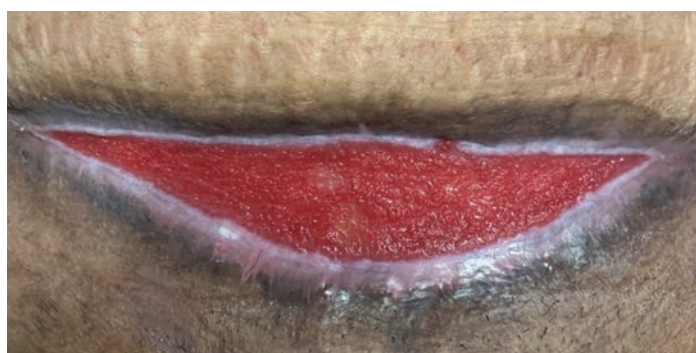Myriad Matrix 5-layer



Week 2



Week 5



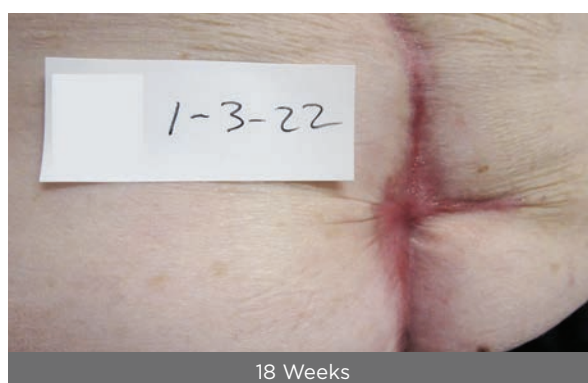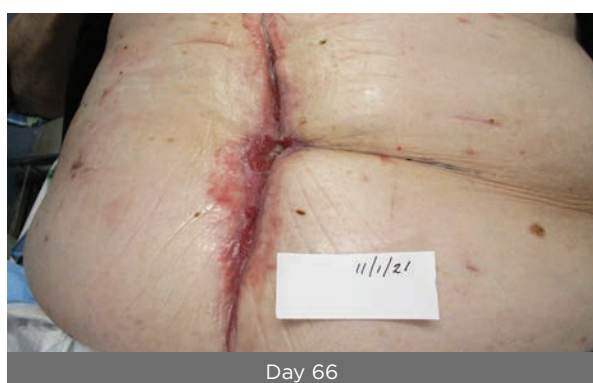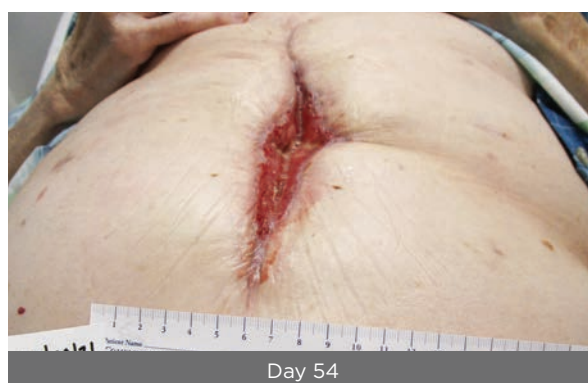
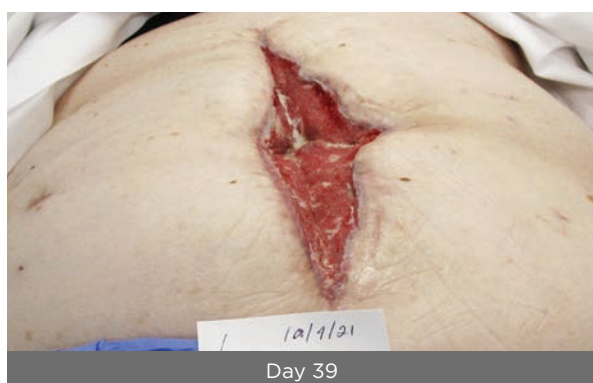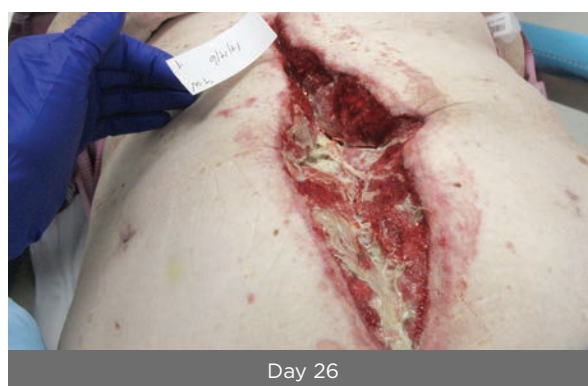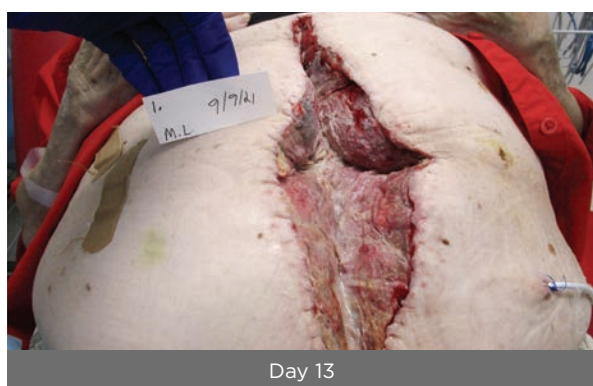Week 10

CC.0195

Clinical Case Series: Abdominal Defects

Abdominal dehiscence following hernia repair revision

75-Year-old female with obesity, hyperlipidemia, hypertension and hypothyroidism developed a large wound infection and dehiscence after a ventral hernia repair revision. Myriad Morcells 2000 mg and Myriad Matrix (10 x 20 cm, 3-layer x 2) was applied onto the exposed fascia with underlying synthetic mesh. It was covered with a non-adherent dressing and NPWT. The NPWT foam was changed twice per week but the non-adherent dressing was left in place for 2 weeks to minimize interruption of healing. At day 13, **Myriad was intact and there were no complications or infection. At day 26, there was a ~ 12% reduction in size of the wound and **Myriad** was 90% integrated. Residual **Myriad** was present in the central and distal areas of the wound, which was left intact. A culture of the wound returned a positive result for MRSA and a course of Clindamycin was prescribed. NPWT was held for 72 hours and Dakin's-soaked gauze was placed into the wound bed. By day 39, the antibiotic course had completed and the wound odor had resolved. Residual **Myriad** had fully incorporated and the depth had reduced by ~50%. **Endoform™ Antimicrobial** was placed under NPWT to drive epithelialization. At day 54, there had been ~86% reduction in size and healthy granulation tissue was visible. By week 8 the wound was predominantly closed. At week 18, there was full epithelialization and a good cosmetic outcome. There was no hernia recurrence at 9 months and no mesh infection.**



CC.0081


Myriad Portfolio

Myriad Matrix™

Myriad Matrix is an engineered extracellular matrix (ECM) for soft tissue repair, reinforcement and complex wounds.

AVAILABLE IN

2, 3 and 5-Layers



5 x 5 cm

7 x 10 cm

10 x 10 cm

10 x 20 cm

20 x 20 cm
(2-Layer only)

Myriad Morcells™

Myriad Morcells is a morselized (powdered) format of Myriad Matrix for soft tissue repair and complex wounds. Myriad Morcells works synergistically with Myriad Matrix when used in combination.

AVAILABLE IN



200 mg

500 mg

1000 mg

2000 mg

Myriad Morcells Fine™

Myriad Morcells Fine delivers a bolus of biologically important extracellular matrix (ECM) proteins to help kick start and sustain healing. Myriad Morcells Fine works synergistically with Myriad Matrix when used in combination.

AVAILABLE IN



200 mg

500 mg

1000 mg

2000 mg

RX Only. Intended for viewing by healthcare providers only. Results may vary. The content herein does not constitute or contain medical advice. Any medical information provided in the content is of a general nature and is not intended to be a substitute for medical advice, diagnosis or treatment of a physician or other qualified health provider.

Prior to use of this device, be sure to read the complete information on how to use this device including Warnings, Precautions, Contraindications and Instructions for Use and all other package inserts supplied with the product.

Not all devices are registered and approved for sale in all countries or regions and indications for use may vary by country or region. Please contact your local representative for more information.

For product questions, sampling needs, or detailed questions concerning our products, please contact us:

For the US: P 1-877627-6224 | E customerservice@aroa.com

For all other countries: call your local representative or email globalsales@aroa.com

Xeroform® is a trademark and property of its respective owner. **ARO A™, Myriad™, Myriad Matrix™, Myriad Morcells™, Morcells™, Endoform™ Antimicrobial** and **ARO A ECM™** are trademarks of Aroa Biosurgery Limited.



ARO A™

www.aroa.com

MKT.1968.01 | ©January 2025