

# Myriad™

Soft Tissue Bioscaffold

## Clinical Case Series

# Necrotizing Soft Tissue Infections (NSTIs)

---

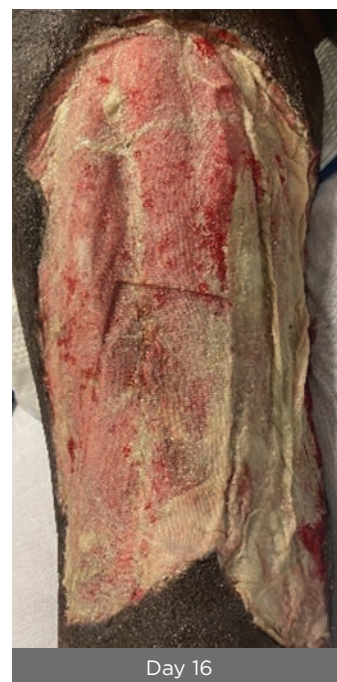
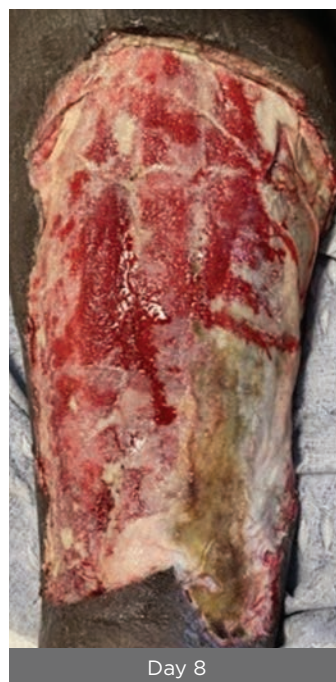
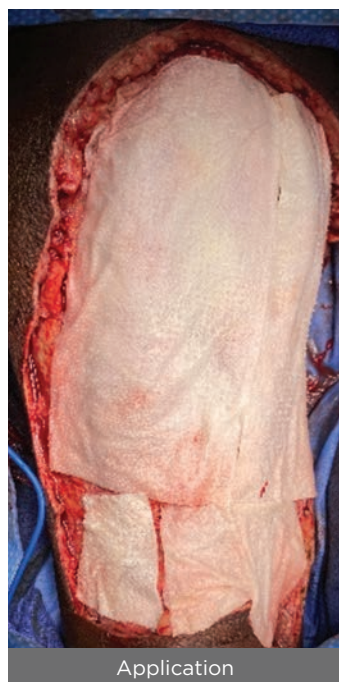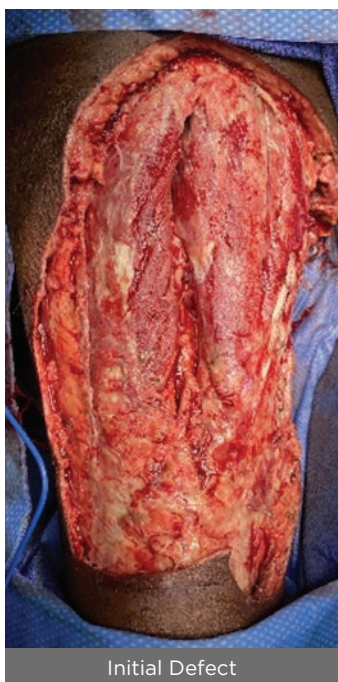## Clinical Case Series: Necrotizing Soft Tissue Infections

### NSTI of the thigh

**56-Year-old, trans male. Full thickness wound of the left posterior thigh with exposed hamstrings muscle and tendon.**

Approximate size: 21 x 10 x 2 cm. Multiple sharp debridements of nonviable tissue were performed and multiple pieces of **Myriad Matrix™** 10 x 20 cm 5-layer were sutured into place. At day 28, 100% vascularized, granular neodermis had formed with no complications. Split thickness skin graft applied at day 35 (not shown) with 100% take of the skin graft and no complications.<sup>1</sup>

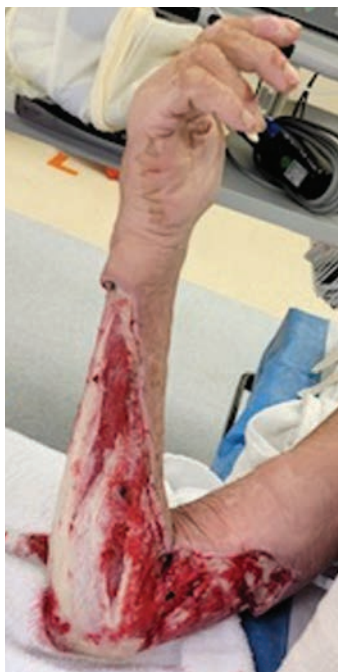

CC.0156

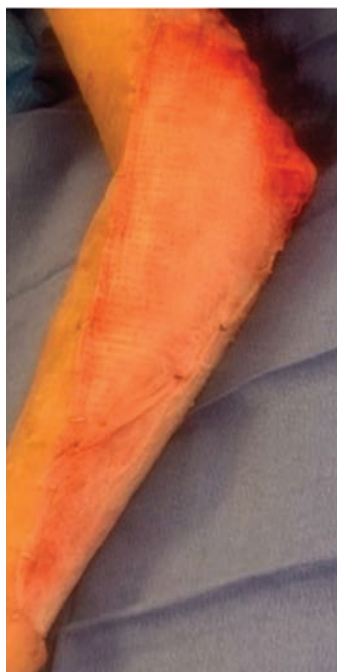## Clinical Case Series: Necrotizing Soft Tissue Infections

### Upper extremity NSTI

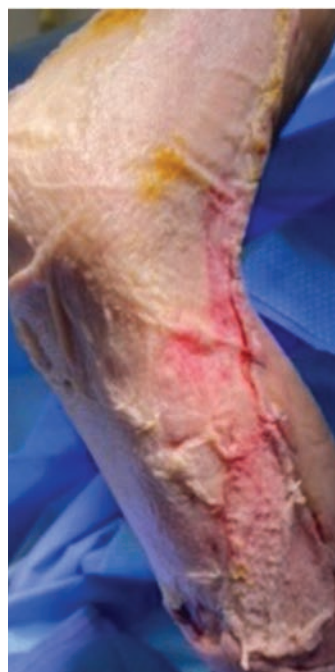**57-Year-old, male. Schizophrenia with chronic renal failure.** Wound of unknown etiology. Three pieces of **Myriad Matrix** 10 x 20 cm, 3-layer were sutured to the perimeter of the debrided defect. By day 8, the graft was well adhered with no complications. By day 25, new dermal tissue was forming.



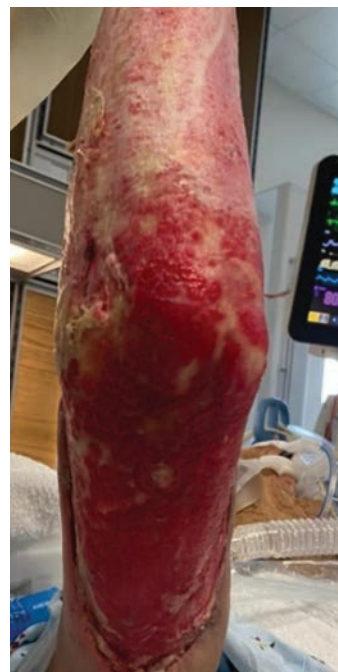Initial Defect



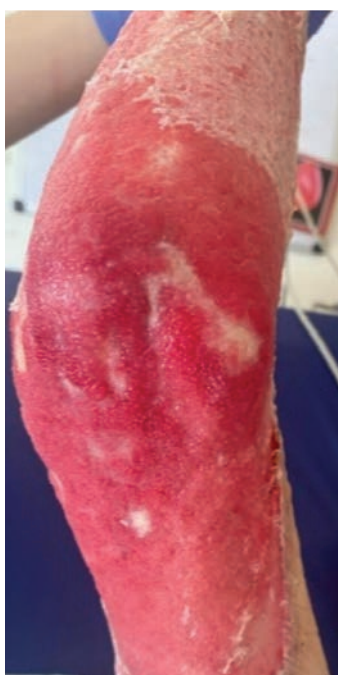Application



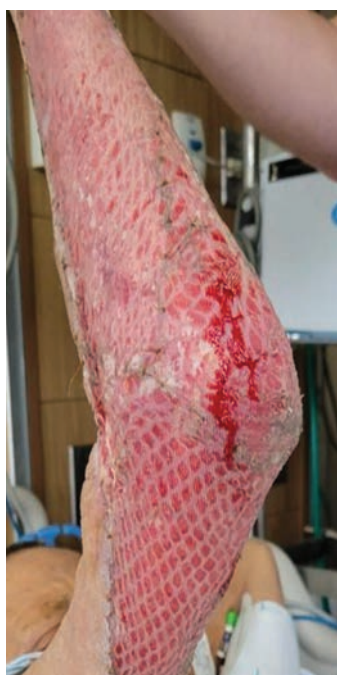Day 8



Day 25



Day 32



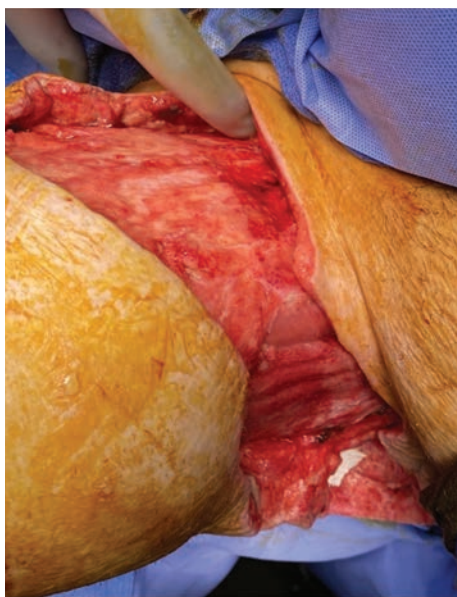Day 34

CC.0080

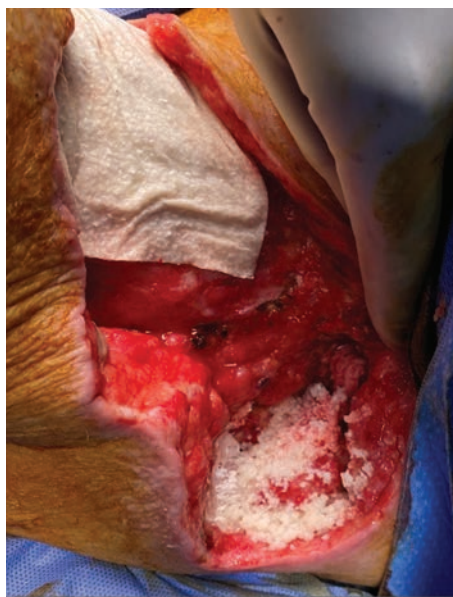## Clinical Case Series: Necrotizing Soft Tissue Infections

### NSTI of the groin

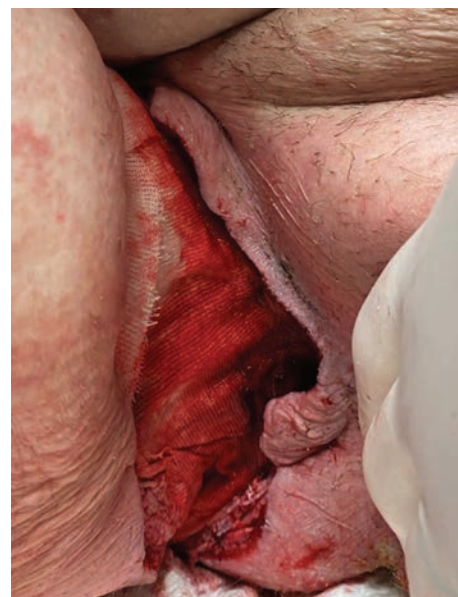
**37-Year-old male with Spina bifida and Fournier's gangrene.** Patient developed a full thickness, contaminated right groin wound due to an NSTI. Approximate size was 30 x 10 x 3 cm with circumferential undermining. **Myriad Morcells™** 2000mg was packed into the deepest part of the wound. Then two **Myriad Matrix** devices, 10 x 20 cm (3-layer and 5-layer) were placed into the undermining and tacked down with absorbable sutures. By week 6, the depth had filled, undermining had been eradicated and a 50% reduction in wound area was noted. By week 7 the wound was ready for STSG.<sup>1</sup>



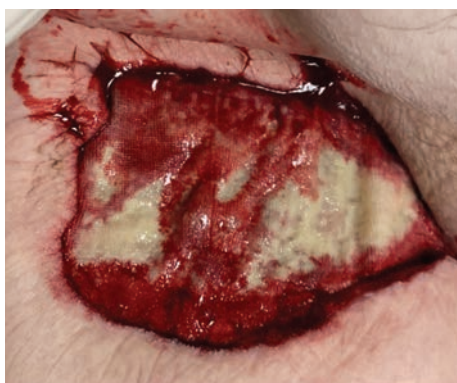Initial Defect



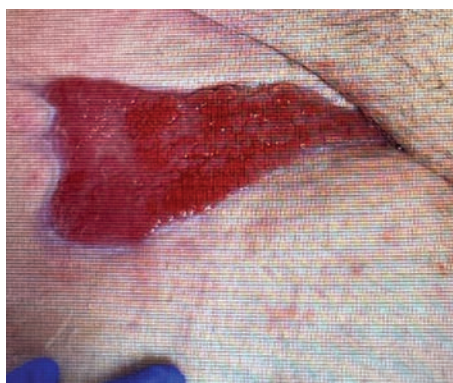Myriad Application



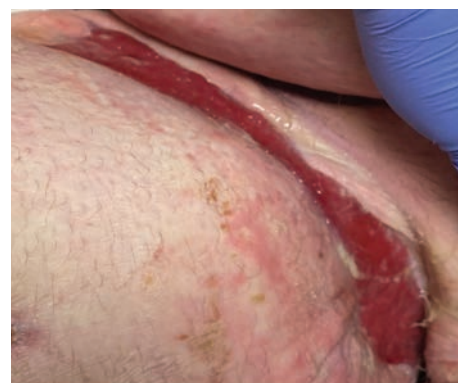Week 1



Week 2



Week 6



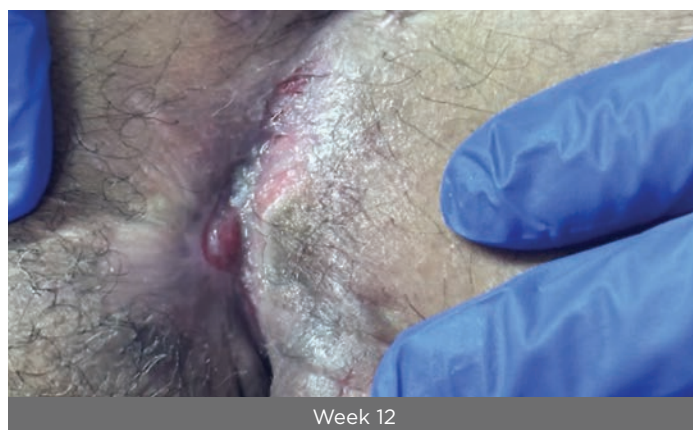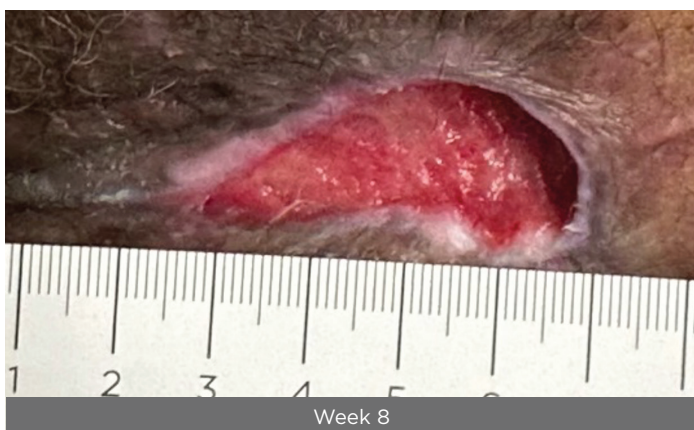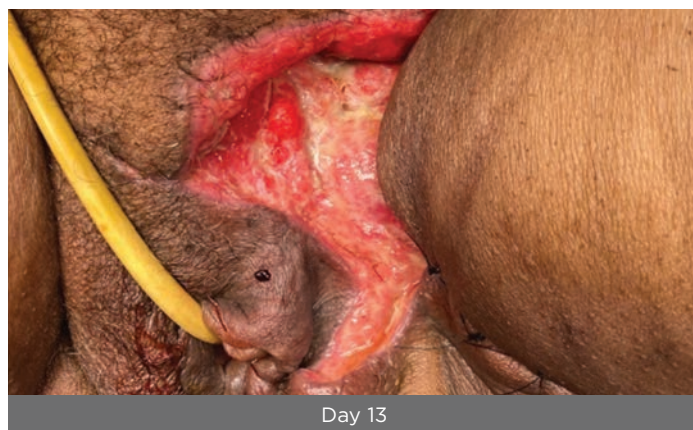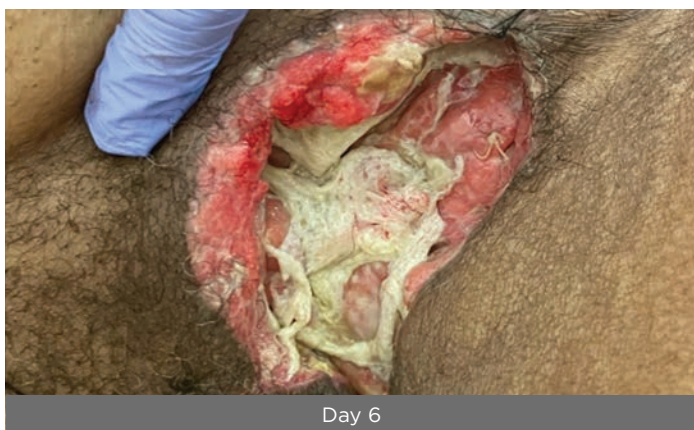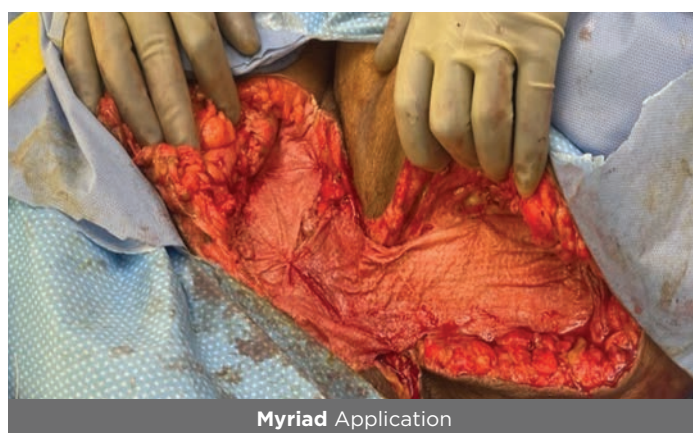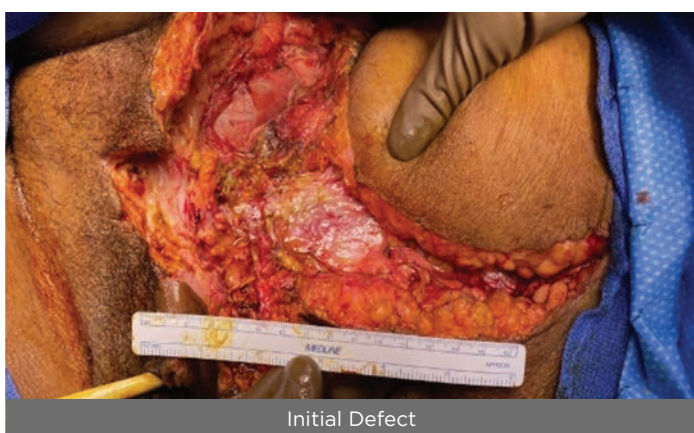Week 12

CC.0165

## Clinical Case Series: Necrotizing Soft Tissue Infections

### NSTI of the groin

**72-Year-old female with autoimmune hepatitis, morbid obesity, diabetes and chronic kidney disease.** Patient developed an NSTI of the left groin requiring debridement. Approximate size was 18 x 15 x 2 cm. Four days post debridement, **Myriad Matrix** 10 x 20 cm, 3-layer was applied to the entire defect including areas of undermining and partially closed (note: half of **Myriad Matrix** was thereby implanted while the remainder of the device was left opened). By day 6, the closed portion was healing well with residual **Myriad** noted in the opened portion. At day 13, significant improvement in depth and granulation tissue was noted. At week 8 the wound area and depth had significantly reduced. At week 12 there was near full epithelialization.<sup>1</sup>

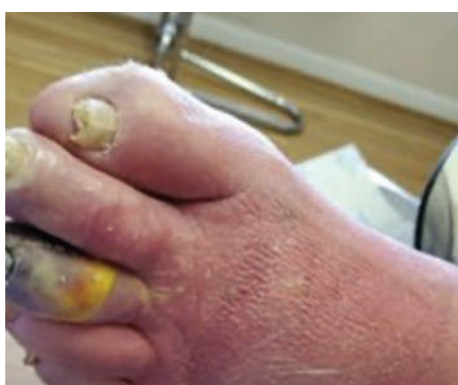

CC.0170

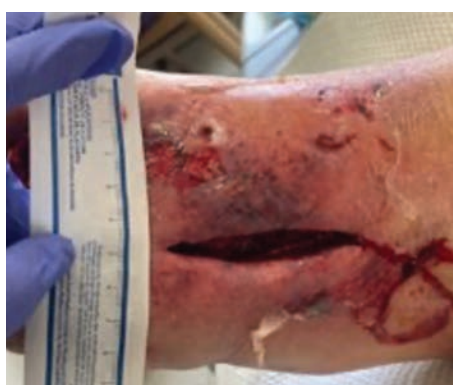## Clinical Case Series: Necrotizing Soft Tissue Infections

### Wagner 4 DFU with NSTI

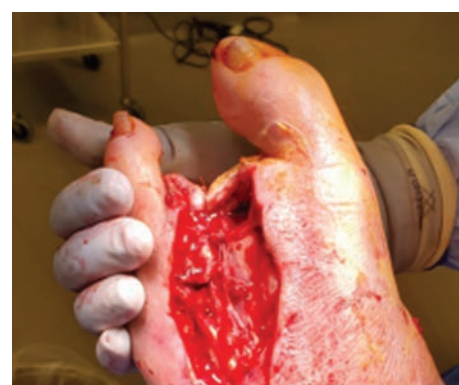**73-Year-old male with Type 2 diabetes mellitus, peripheral arterial disease and coronary artery disease.** Patient developed a significant infection resulting in multiple left lower extremity wounds including necrotizing fasciitis/gas gangrene of the third toe. In a staged procedure, the third and second toe were amputated followed by multiple foot and leg fasciotomies. The approximate wound size was 10.1 x 3.8 x 1.2 cm with exposed bone and tendon. Four days post second procedure, a final debridement of non-viable tissue was performed. **Myriad Morcells** 1000 mg was applied followed by **Myriad Matrix** 10 x 10 cm. At 2.5 weeks, improved depth and granulation tissue were noted with no complications. At week 7 a STSG was applied. At week 10 there was 90% take of the STSG which had fully epithelialized by week 12 with minimal scarring and skin fibrosis.<sup>2</sup>



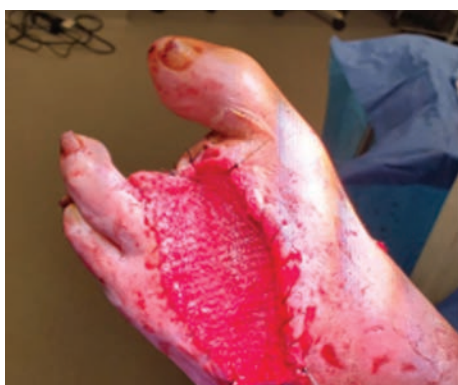Initial Defect



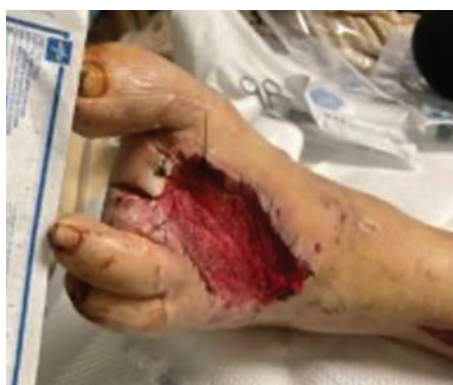1<sup>st</sup> Procedure



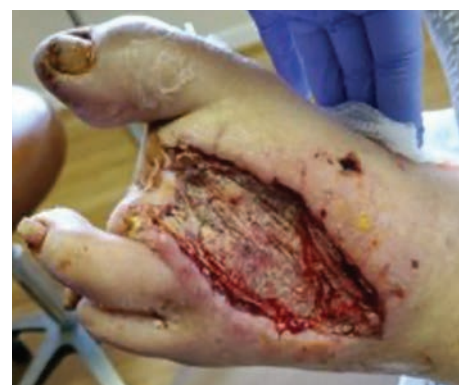2<sup>nd</sup> Procedure



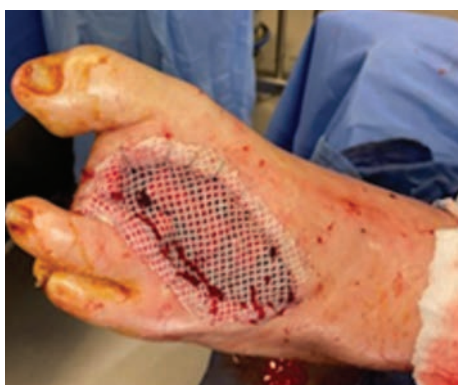Myriad Application



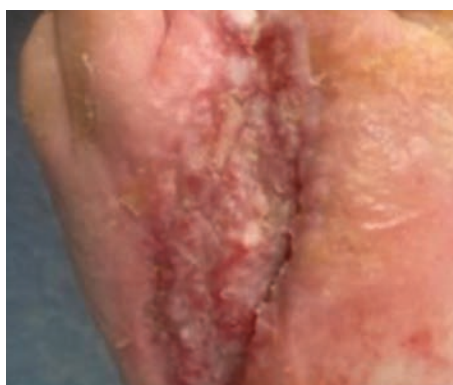Day 4



Week 2.5



Week 7



Week 10

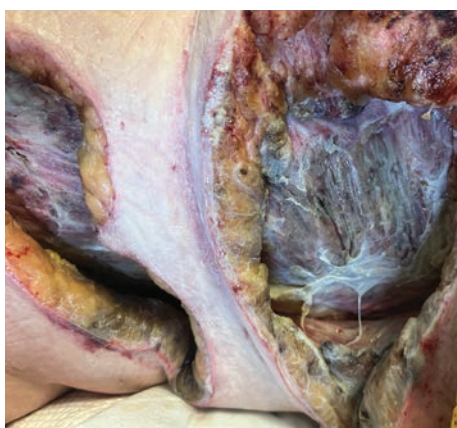CC.0040

## Clinical Case Series: Necrotizing Soft Tissue Infections

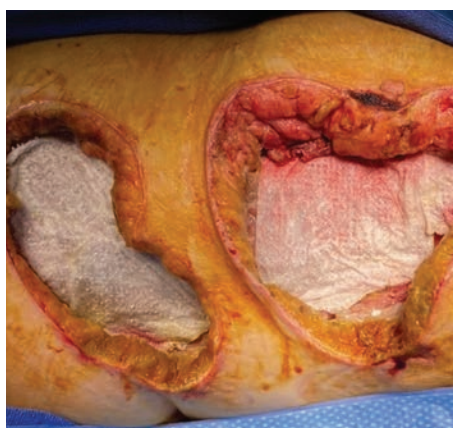
### NSTI of the chest

**60-year-old female. Acute chest and abdominal soft tissue injury was sustained following a fall from a truck onto the hitch.**

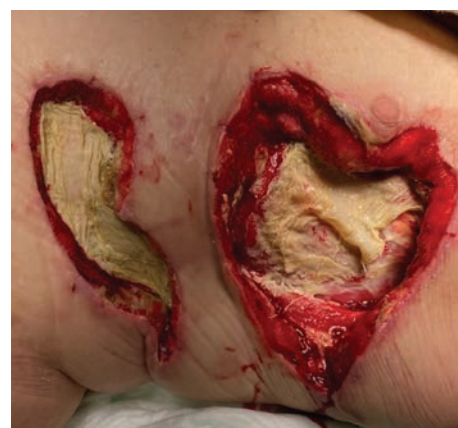The initial defect developed into an NSTI with full thickness ulceration to the thoracic wall. Previous management included multiple surgical debridements and antibiotics. Approximate size of the defect: 21 x 14 x 3 cm. Post debridement, application of two **Myriad Matrix** sheets (10 x 20 cm, 3-layer) trimmed to size to cover the entire defect, including areas of undermining. NPWT was used in conjunction. At day 6, well vascularized peripheral tissue was observed. Residual **Myriad** was noted and kept intact and hydrated with continuation of NPWT. At day 11, further integration of **Myriad** was observed along with formation of vascularized granulation tissue. At day 15, there was nearly complete integration of **Myriad** with improved depth. By day 36 there had been significant depth reduction. By day 57, the depth had been eradicated and a STSG was placed. One week after placement, the graft had 75% take. At week 16, there was full take and epithelialization of the STSG. No complications were reported.



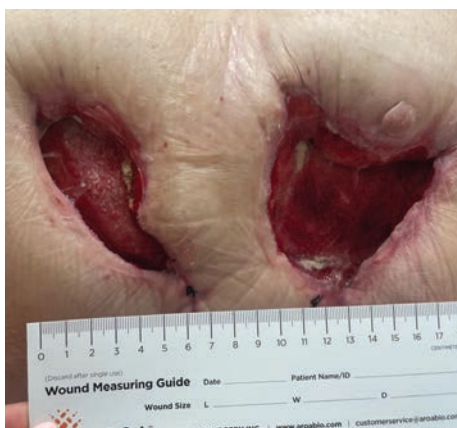Initial Defect



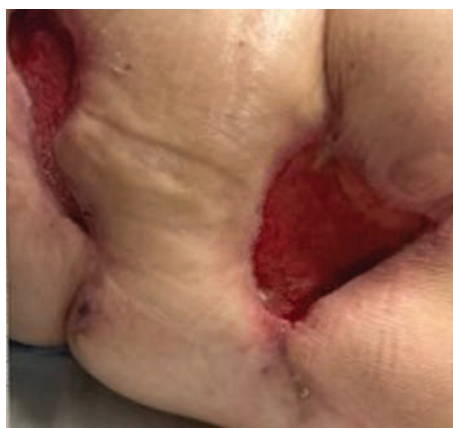Myriad Application



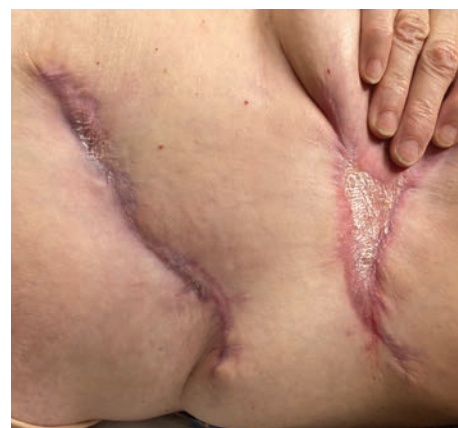Day 6



Day 36



Day 57



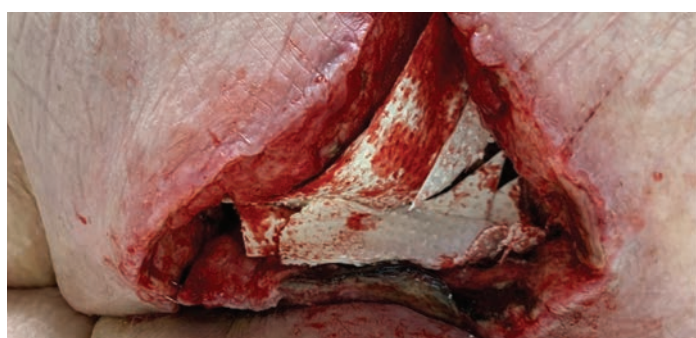Week 16

CC.0178

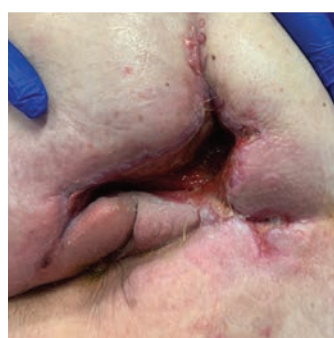## Clinical Case Series: Necrotizing Soft Tissue Infections

### Gluteal and abdominal NSTI

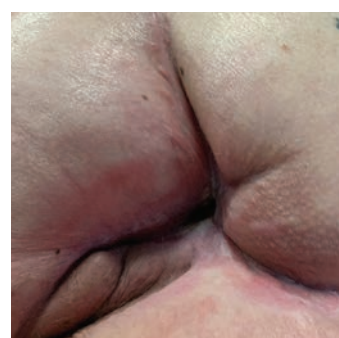**54-Year-old female with hypertension, hyperlipidemia and morbid obesity (BMI 45).** Patient developed a perirectal abscess that progressed to an NSTI of the right gluteus. The infection tracked to the retroperitoneum requiring intraabdominal debridements. The resultant gluteal and abdominal wounds both required reconstruction. The approximate gluteal and abdominal wound sizes were 20 x 15 x 10 cm and 25 x 5 x 4 cm, respectively. **Myriad Matrix** 10 x 20 cm, 3-layer was placed dry and hydrated in situ. By 5 weeks, the periwound inflammation and depth of the cavity had significantly reduced with minimal drainage. By 9 weeks, the gluteal wound was 100% healed and the resulting tissue was soft and pliable. The abdominal wound was 95% healed with the inferior portion significantly improved. By 12 weeks, the abdominal wound was fully healed.



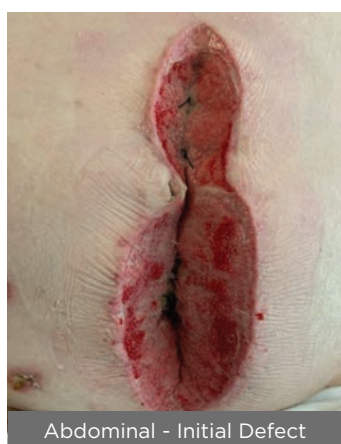Abdominal - Initial Defect



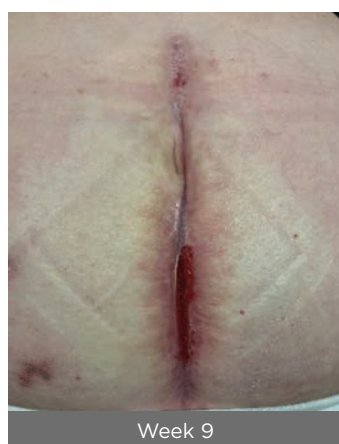Week 5



Week 9



Abdominal - Initial Defect



Week 9

CC.0045

1. Ovine Forestomach Matrix in the Surgical Management of Complex Volumetric Soft Tissue Defects: A Retrospective Pilot Case Series. Cormican, M T., et al. (2023). "Ovine Forestomach Matrix in the Surgical Management of Complex Volumetric Soft Tissue Defects: A Retrospective Pilot Case Series" *Eplasty*. 2023; 23:e66.
2. Bosque, B. A., S. G. Dowling, B. C. H. May, R. Kaufman, I. Zilberman, N. Zolfaghari, H. Que, J. Longobardi, J. Skurka, J. E. Geiger and M. M. Melin (2023). "Ovine Forestomach Matrix in the Surgical Management of Complex Lower-Extremity Soft-Tissue Defects: A Retrospective Multi-Center Case Series." *J Am Podiatr Med Assoc* 113(3): 22-081.

**RX Only.** Intended for viewing by healthcare providers only. Results may vary. The content herein does not constitute or contain medical advice. Any medical information provided in the content is of a general nature and is not intended to be a substitute for medical advice, diagnosis or treatment of a physician or other qualified health provider.

Prior to use of this device, be sure to read the complete information on how to use this device including Warnings, Precautions, Contraindications and Instructions for Use and all other package inserts supplied with the product.

Not all devices are registered and approved for sale in all countries or regions and indications for use may vary by country or region. Please contact your local representative for more information.

**For product questions, sampling needs, or detailed questions concerning our products, please contact us:**

For the US: P 1-877627-6224 | E customerservice@aroa.com

For all other countries: call your local representative or email globalsales@aroa.com

**AROA™, Myriad™, Myriad Matrix™, Myriad Morcells™ and AROA ECM™** are trademarks of Aroa Biosurgery Limited.

 **AROA™**  
www.aroa.com

MKT.1932.01 | © December 2023