

Myriad™

Soft Tissue Bioscaffold

Clinical Case Series

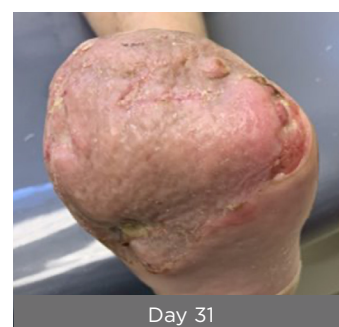
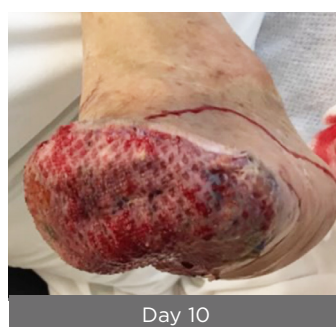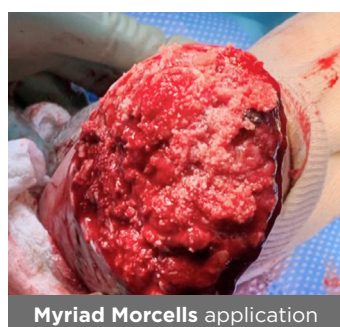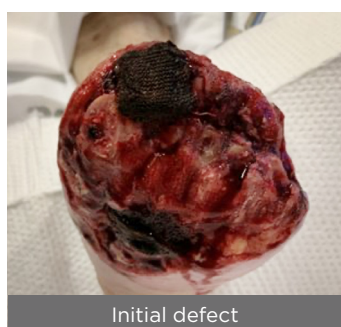Lower Extremity Reconstruction



Clinical Case Series: Lower Extremity Reconstruction

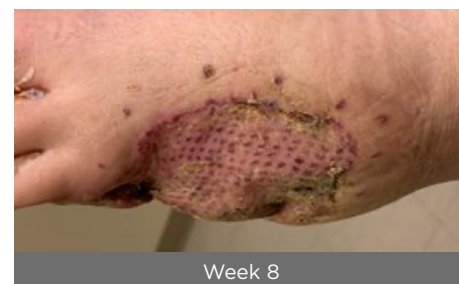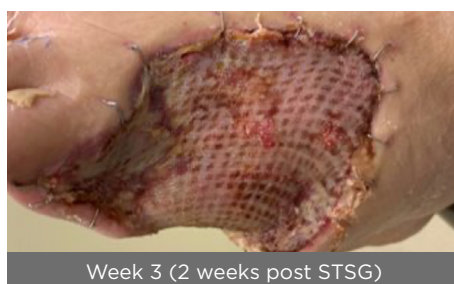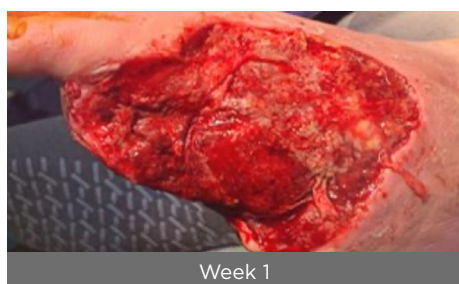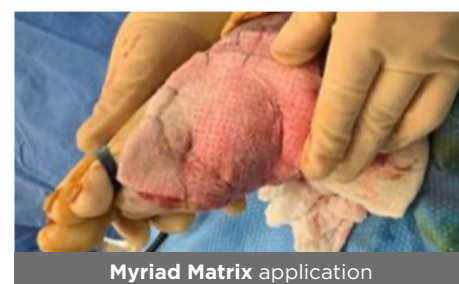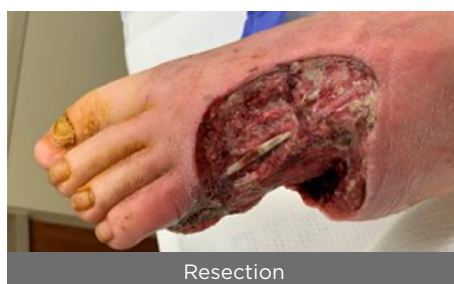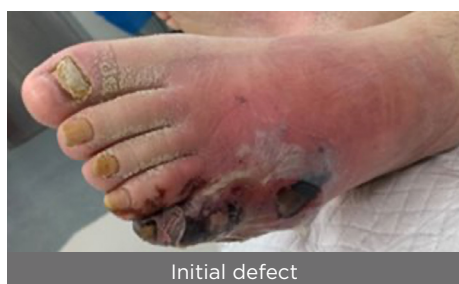Surgical dehiscence post transmetatarsal amputation

74-Year-old, male with uncontrolled diabetes, peripheral vascular disease and chronic kidney disease presented with gangrene and osteomyelitis and a prior forefoot amputation that was open with exposed bone and tendon. Debridement of non-viable soft tissue and bone was performed. **Myriad Morcells™** 500 mg was applied directly to the wound bed followed by **Myriad Matrix™** 10 x 10 cm, 5-layer stapled into place. By day 10, **Myriad™** was well integrated and vascularized with no complications. A STSG was placed. One week later, there was 90% graft take. By day 31, the graft had fully epithelialized with robust, functional tissue.



Necrotizing soft tissue infection of the foot

28-Year-old, male with insulin-dependent diabetes presented with a necrotizing soft tissue infection and sepsis of the foot. In a staged procedure, debridement of non-viable soft tissue and bone was performed resulting in a volumetric defect with exposed tendon and bone. At the second stage, **Myriad Matrix** 10 x 10 cm, 5-layer was applied directly to the wound bed and stapled into place followed by NPWT. At week 1, **Myriad** was well integrated revealing 100% viable granulation tissue and full coverage of bone and tendon. A STSG was placed. At week 3 there was 90% graft take. By week 8 the STSG had fully integrated with a pliable scar. The foot was functional and the patient was able to wear shoes and return to work. There was no recurrence at 6 months.

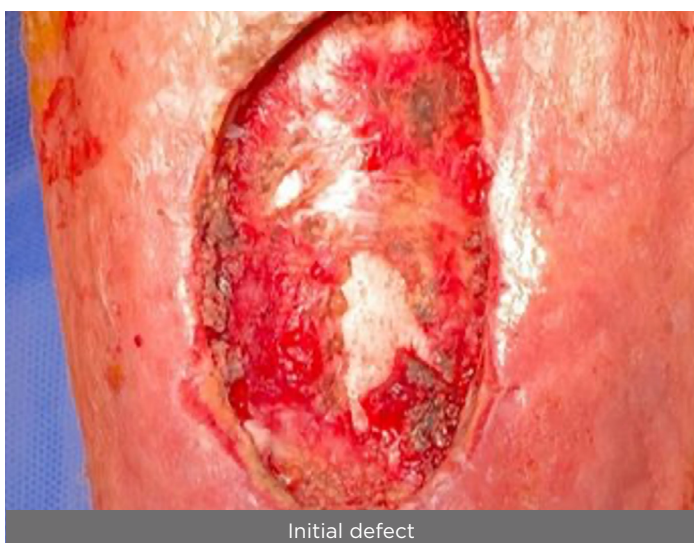

CC.0030.00

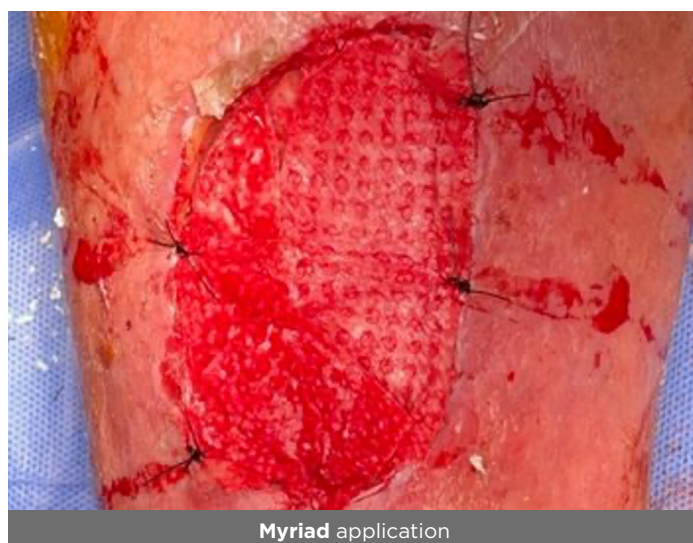
Clinical Case Series: Lower Extremity Reconstruction

Hematoma with exposed muscle and tibia

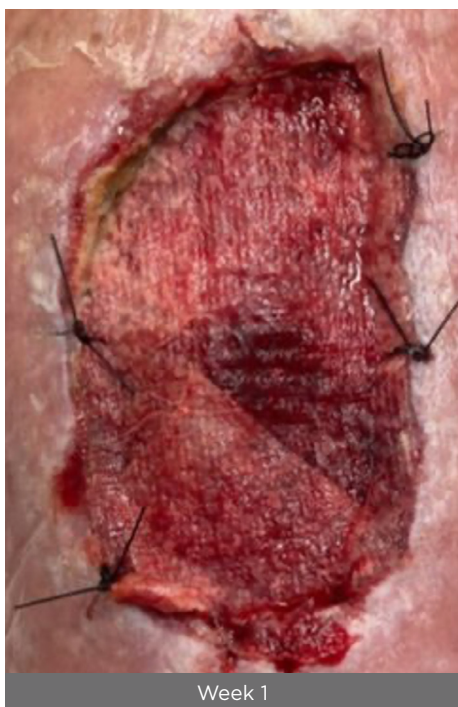68-Year-old, male presented following a traumatic fall and sustaining bilateral deep leg hematomas. These were left untreated for 1.5 months results in significant necrotic nonviable tissue and exposed muscle belly. The patient underwent debridement and application of **Myriad Morcells** 1000 mg to the undermined areas and then overlaid with **Myriad Matrix** 10 x 10 cm 5-layer followed by NPWT. After 1 week, **Myriad Matrix** was well adhered with observed granulation formation. By week 3, residual **Myriad Matrix** was gently debrided to reveal well vascularized granulation tissue and coverage of exposed muscle and bone. By week 12, a small area (<1 cm²) remained. The patient went on to heal.



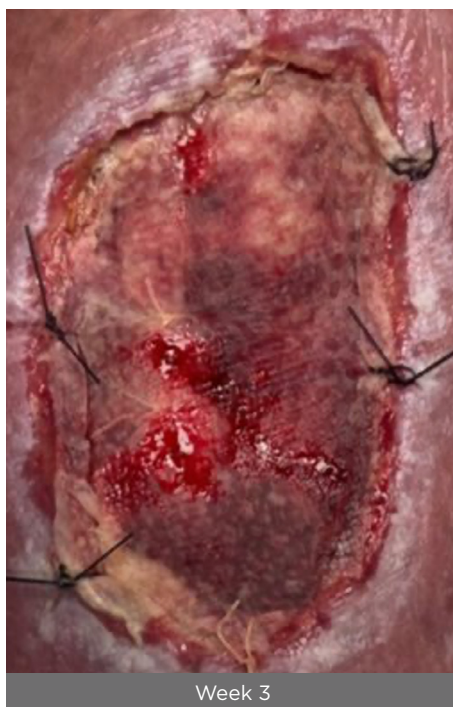Initial defect



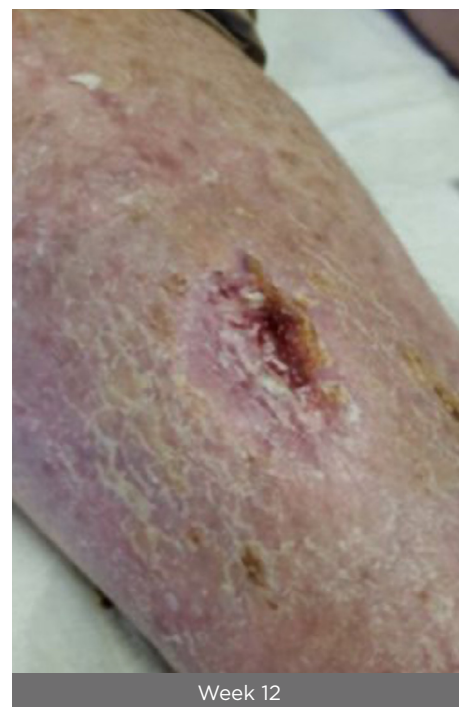Myriad application



Week 1



Week 3



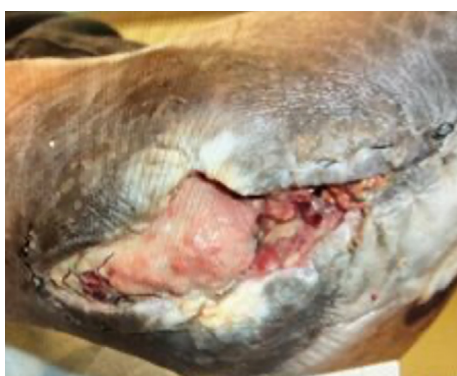Week 12

CC.0039.00

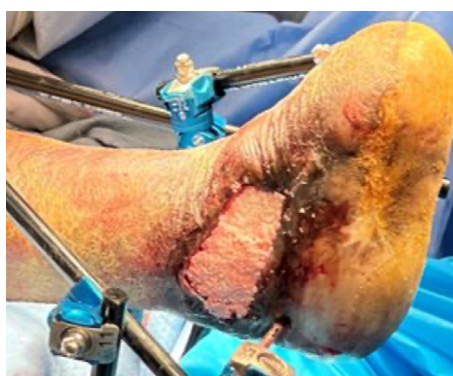Clinical Case Series: Lower Extremity Reconstruction

Chronic lower extremity wound

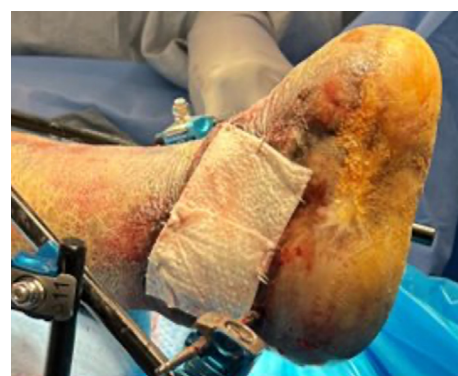40-Year-old male with uncontrolled diabetes, peripheral vascular disease and a prior amputation, developed a full thickness ulcer of the right lateral foot with exposed bone and tendon. The wound had been present for 9 years with chronic osteomyelitis and multiple prior abscesses. The approximate wound size was 4 x 2 x 0.3 cm. A talectomy and application of external fixation was performed to address angular deformity and stabilize the ankle. Five months later, **Myriad Morcells** 500 mg was applied with **Myriad Matrix** 10 x 10 cm, 5-layer overlaid. At 3 weeks, budding of granulation tissue was noted with good integration of **Myriad** into the wound bed. At week 10, vascular neodermis had formed with visible epithelialization. Final closure by secondary intention was planned and by week 14 there was near full epithelialization.



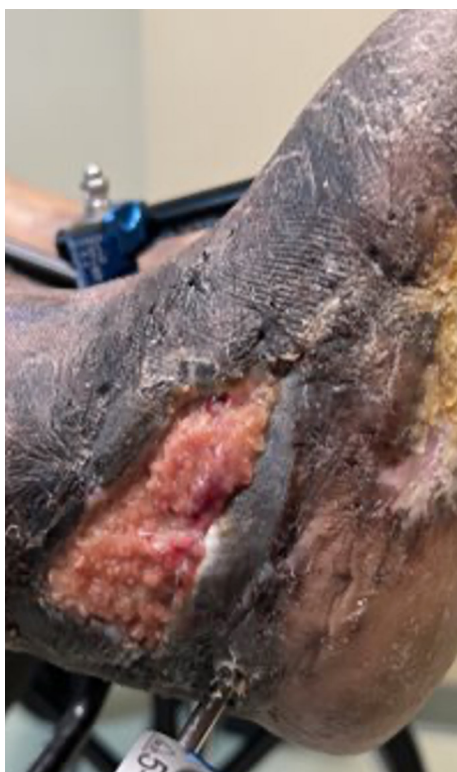Initial defect



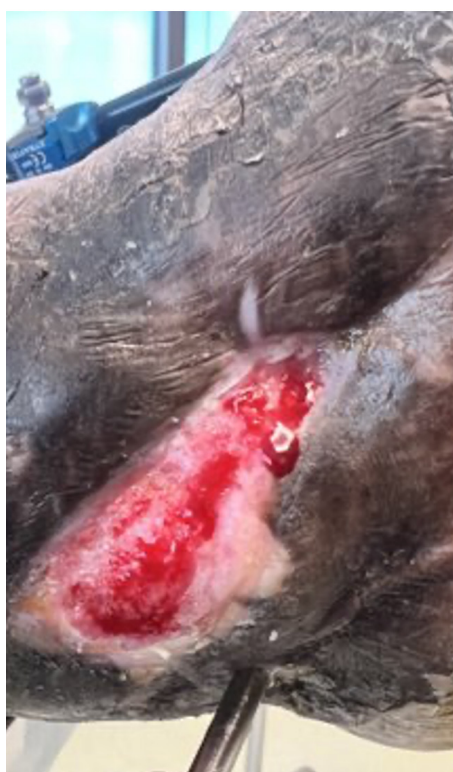Myriad Morcells application



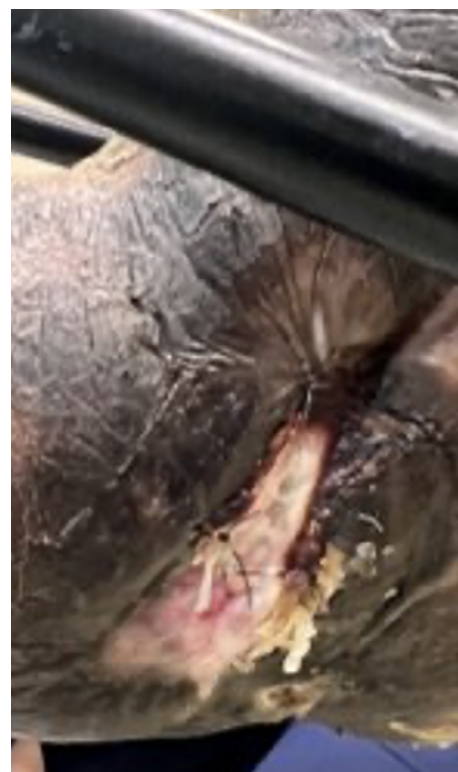Myriad Morcells application



Week 3



Week 10



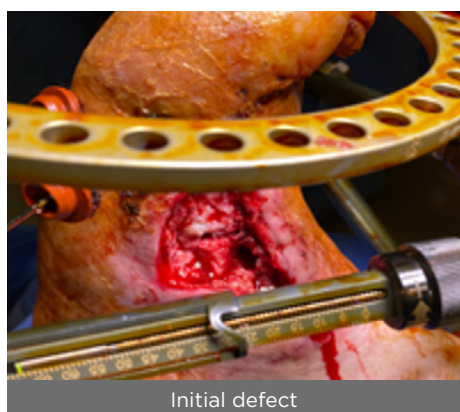
Week 14

CC.0150.00


Clinical Case Series: Lower Extremity Reconstruction

Charcot Reconstruction Dehiscence with exposed bone and joint

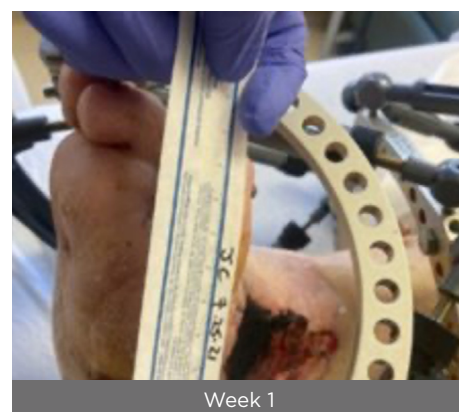52-Year-old, male with uncontrolled type 2 diabetes, Charcot Arthropathy and peripheral arterial disease presented with a full thickness wound with deep sinus and exposed bone and joint. The patient had a surgical dehiscence status post a triple arthrodesis/medial column fusion with internal and external fixation. Following left ankle debridement with an external fixator, **Myriad Morcells** 1000mg was applied into the deep tunnel with **Myriad Matrix** 5 x 5 cm, 3-layer overlaid followed by NPWT. By week 1, **Myriad** had well adhered. By week 2, robust granulation was observed, the depth had 100% filled and the bone and joint was covered. The patient was a poor candidate for a STSG so the patient was returned to the OR to remove the external fixator and a second application of **Myriad Matrix** was made. By week 4 (from the initial procedure and day 5 from second placement of **Myriad Matrix**), NPWT was discontinued, and a bolster dressing was applied. By week 6, residual **Myriad** was gently debrided revealing 100% granular wound bed, 100% depth of wound with viable soft tissue. By week 10, the wound was 80% epithelialized and by week 12, the wound had 100% healed by secondary intention with **Endoform™**.



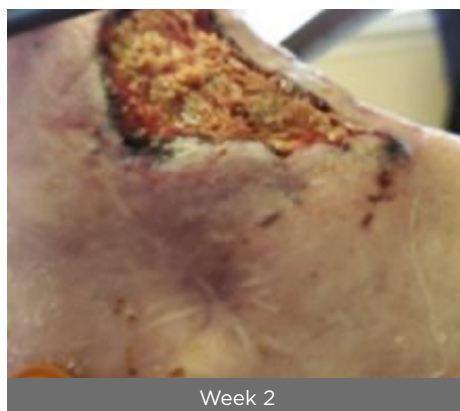Initial defect



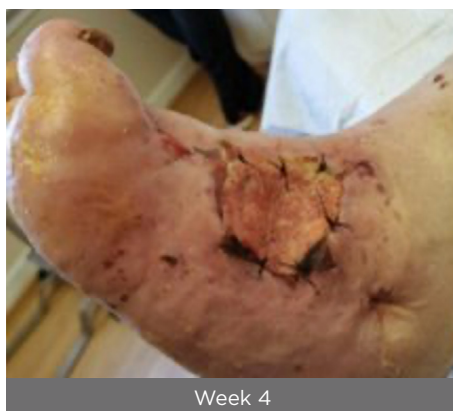Application



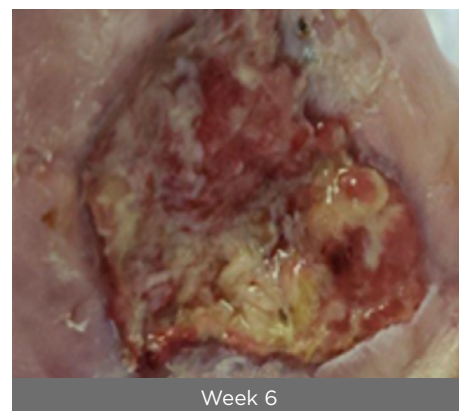
Week 1



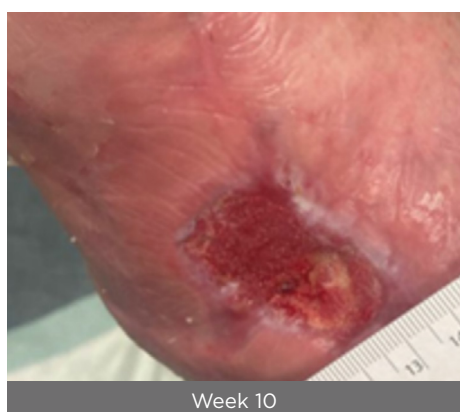Week 2



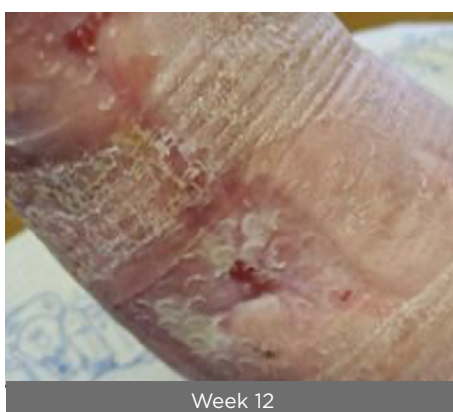Week 4



Week 6



Week 10

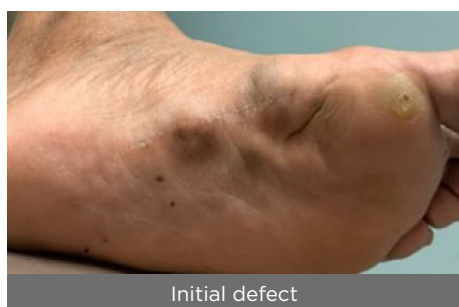

Week 12

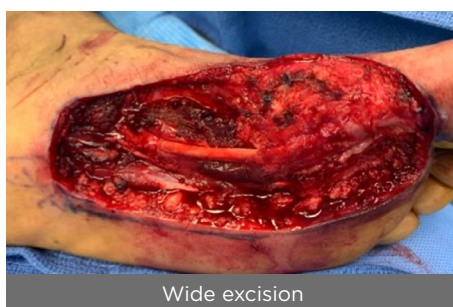Clinical Case Series: Lower Extremity Reconstruction

Plantar fibromatosis reconstruction

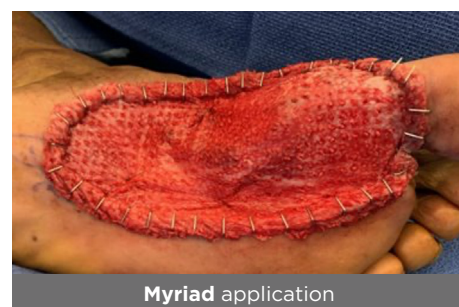60-Year-old, male presented with recurrent plantar fibromatosis of the left foot and in significant discomfort. The patient had received 3 local excisions previously. The patient underwent a full thickness dissection with wide margins. **Myriad Matrix** 10 x 20 cm 3-layer was applied and secured to the wound bed with staples. By day 4, **Myriad Matrix** was well adhered and granulation tissue was visible. By day 10, there was complete coverage over exposed tendons. **Endoform** was placed over the 1st MTP joint for more robust coverage, with continuation of NPWT. By day 32 there was complete coverage and the defect had filled with well vascularized tissue. The patient was scheduled for a STSG 2 weeks later.



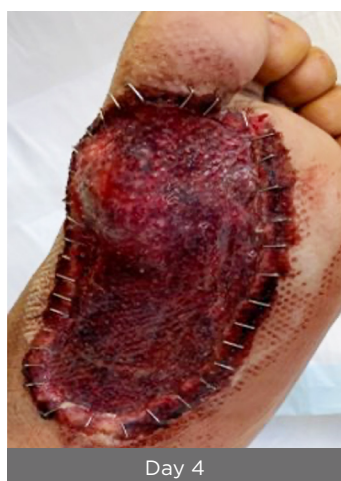Initial defect



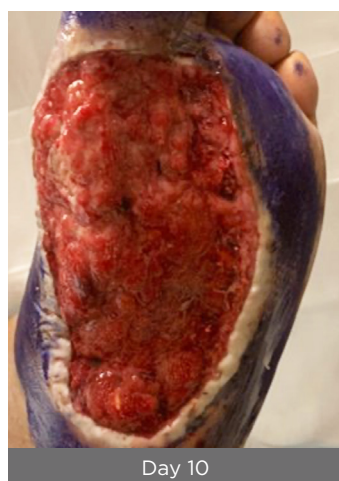Wide excision



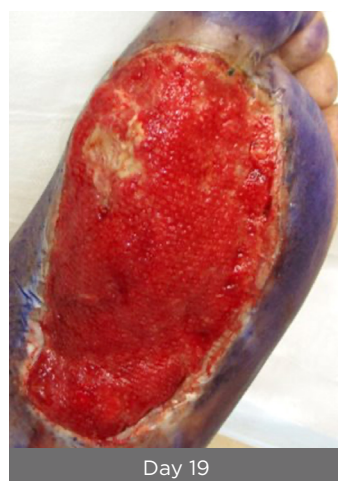Myriad application



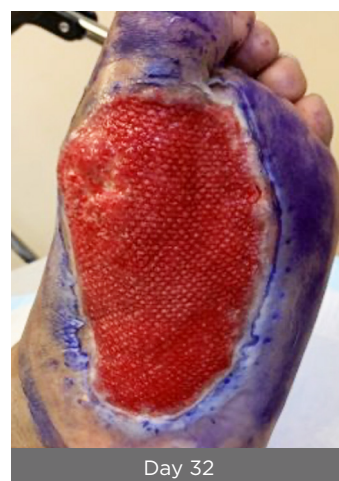Day 4



Day 10



Day 19



Day 32

CC.0078.00

RX Only. Intended for viewing by healthcare providers only. Results may vary. The content herein does not constitute or contain medical advice. Any medical information provided in the content is of a general nature and is not intended to be a substitute for medical advice, diagnosis or treatment of a physician or other qualified health provider.

Prior to use of this device, be sure to read the complete information on how to use this device including Warnings, Precautions, Contraindications and Instructions for Use and all other package inserts supplied with the product.

Not all devices are registered and approved for sale in all countries or regions and indications for use may vary by country or region. Please contact your local representative for more information.

For product questions, sampling needs, or details questions concerning our products, please contact us:

For the US: P 1-877627-6224 | E customerservice@aroa.com

For all other countries: call your local representative or email globalsales@aroabio.com.



AROA™, Myriad Matrix™, Myriad Morcells™, Endoform™ and AROA ECM™ are trademarks of Aroa Biosurgery Limited.

MKT:1948.01 | © November 2023